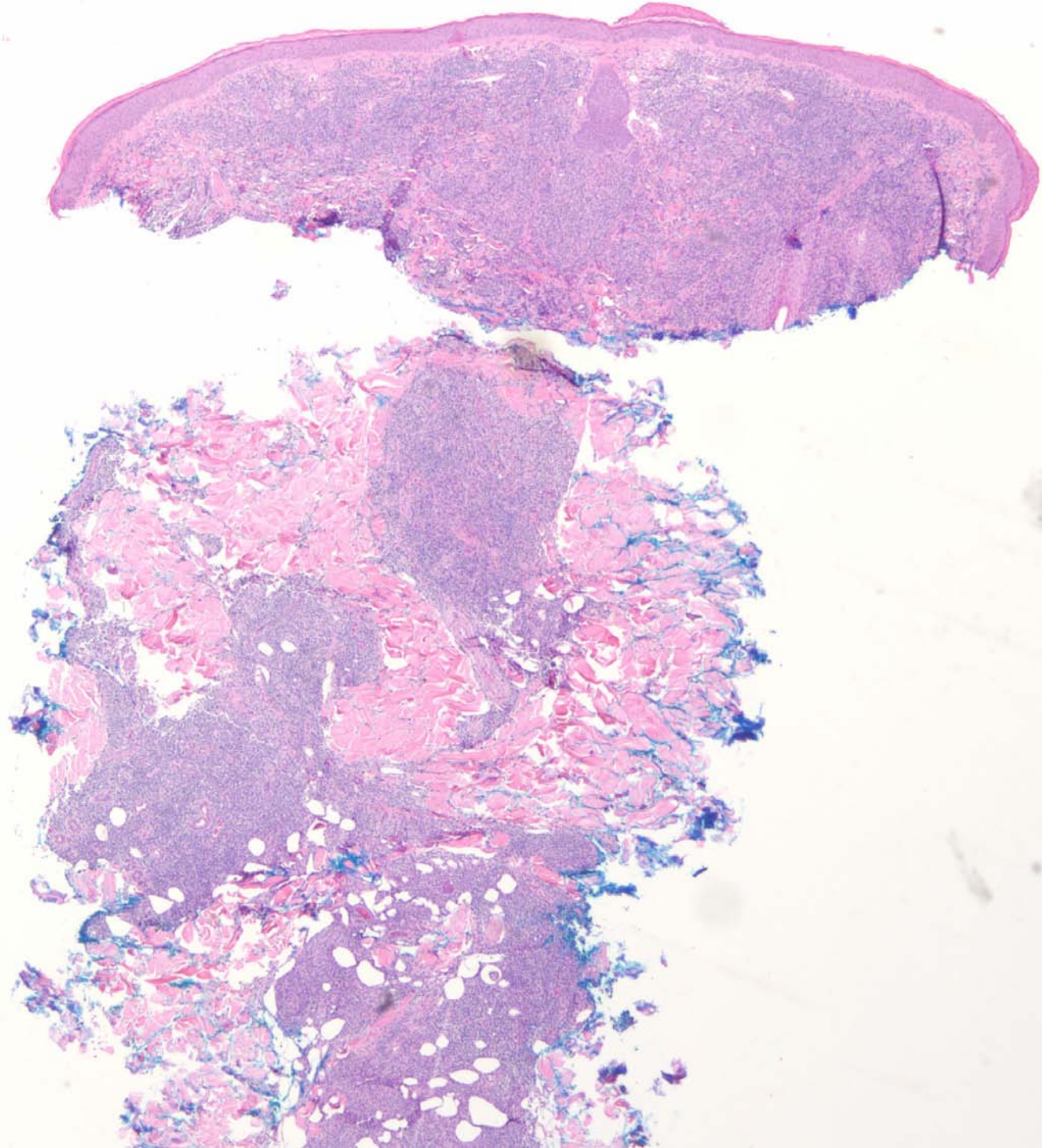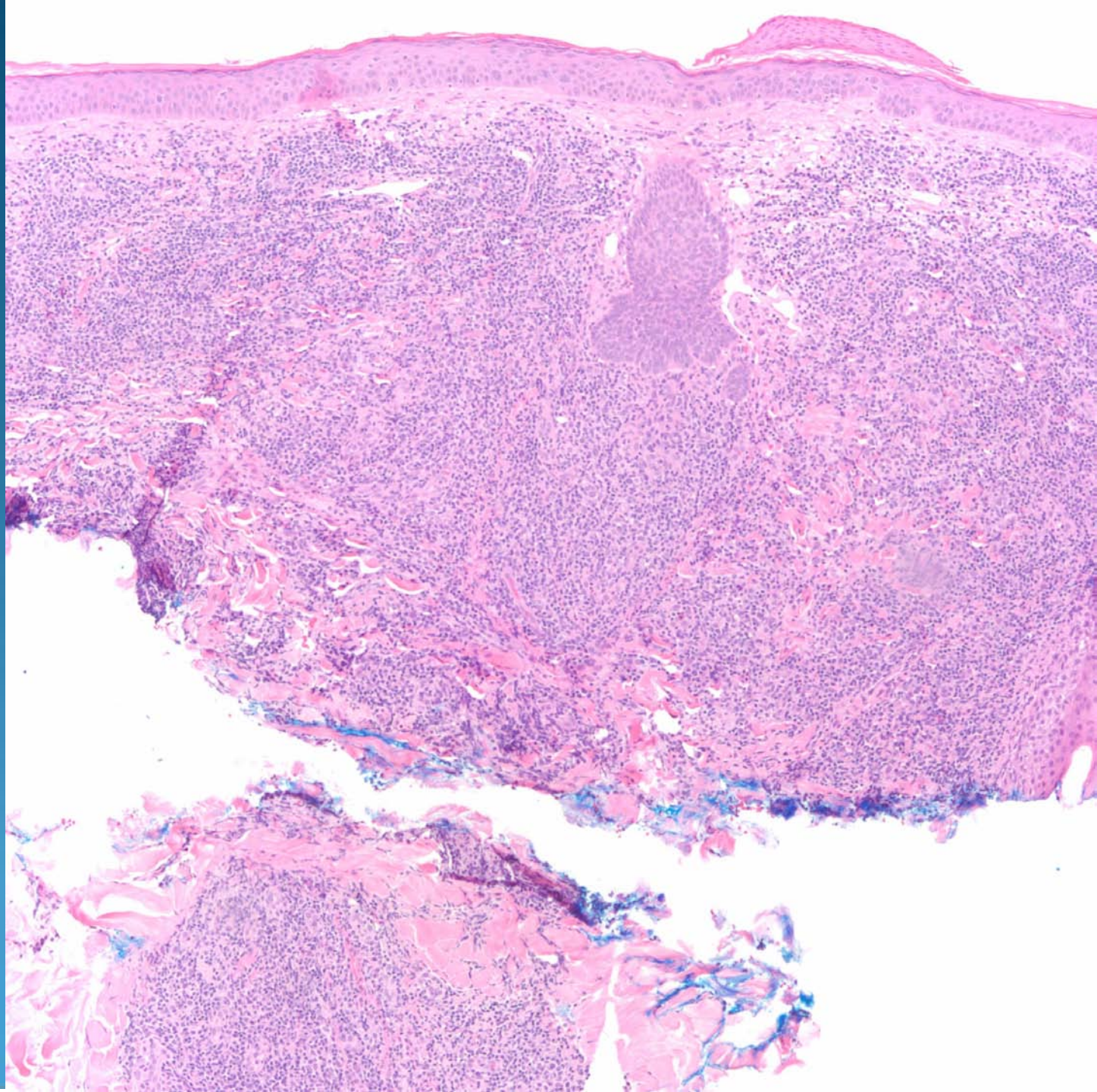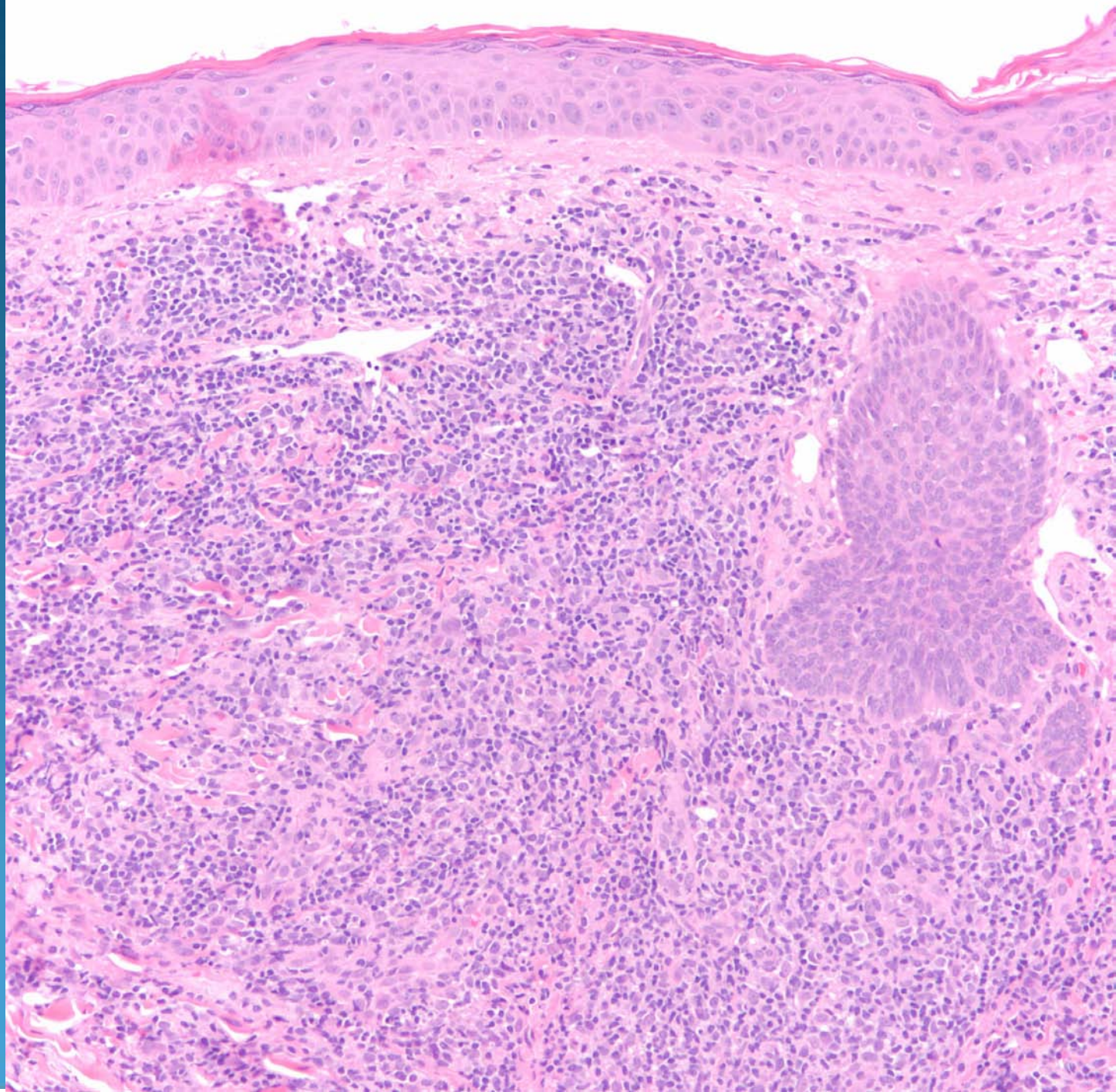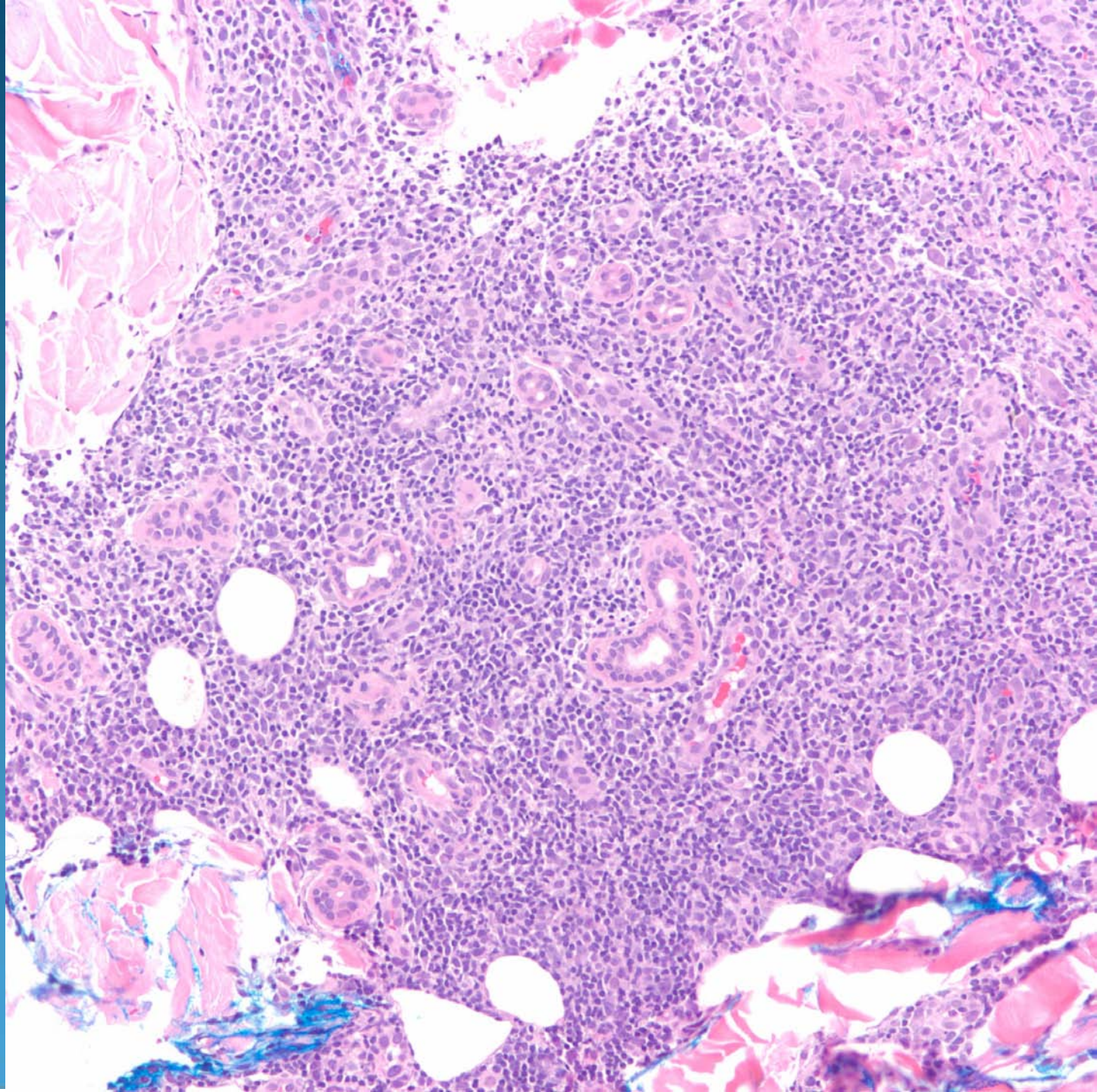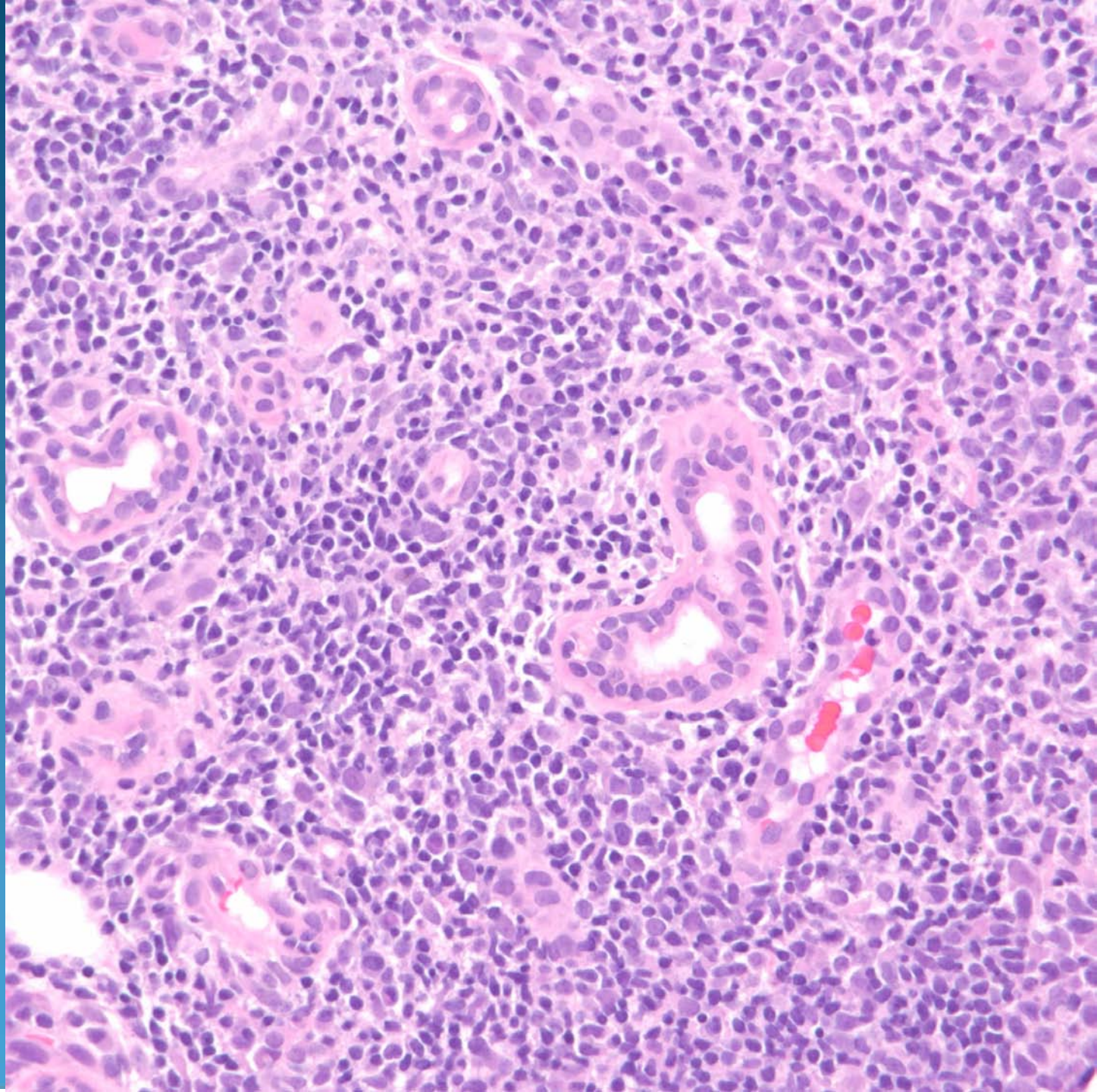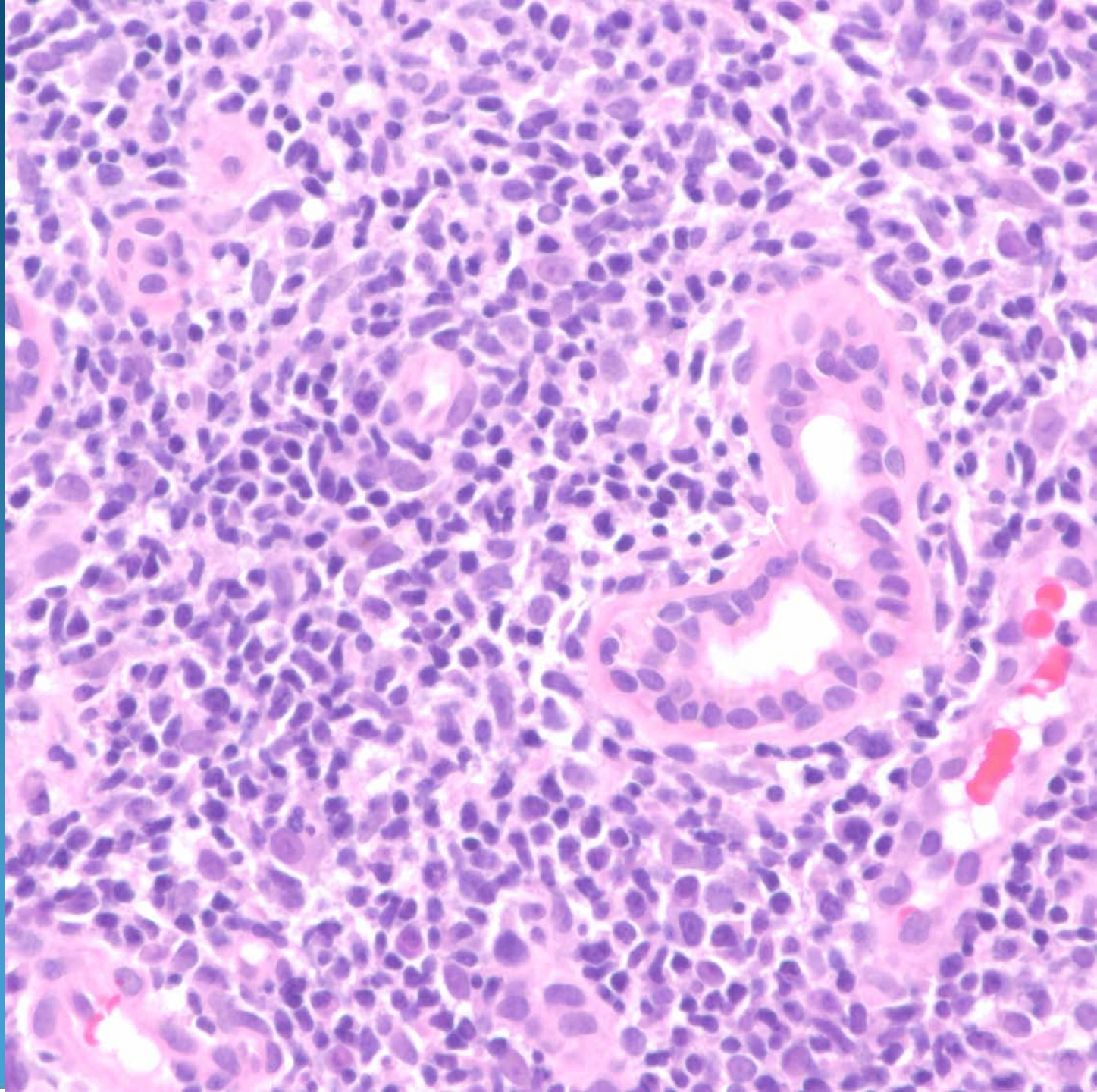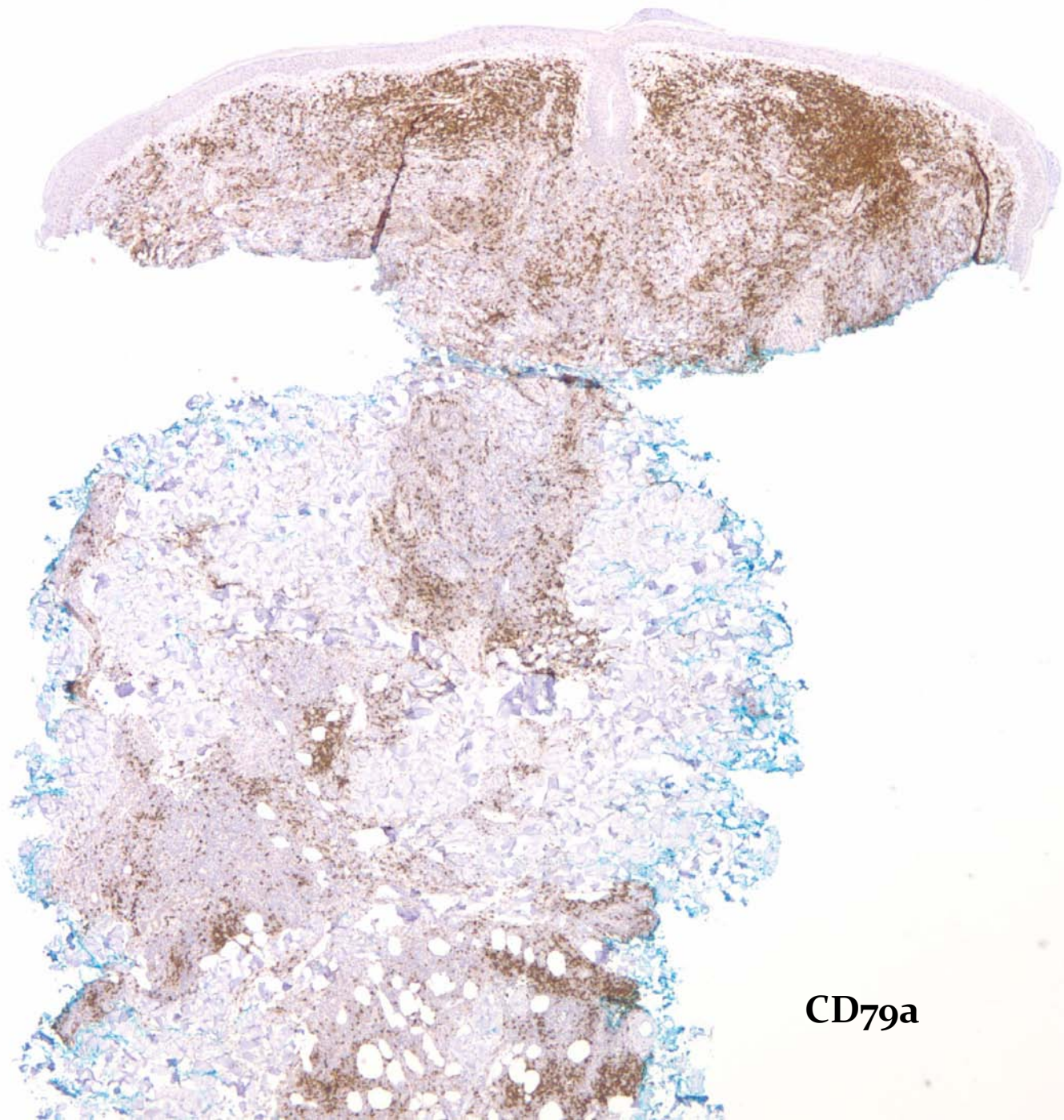
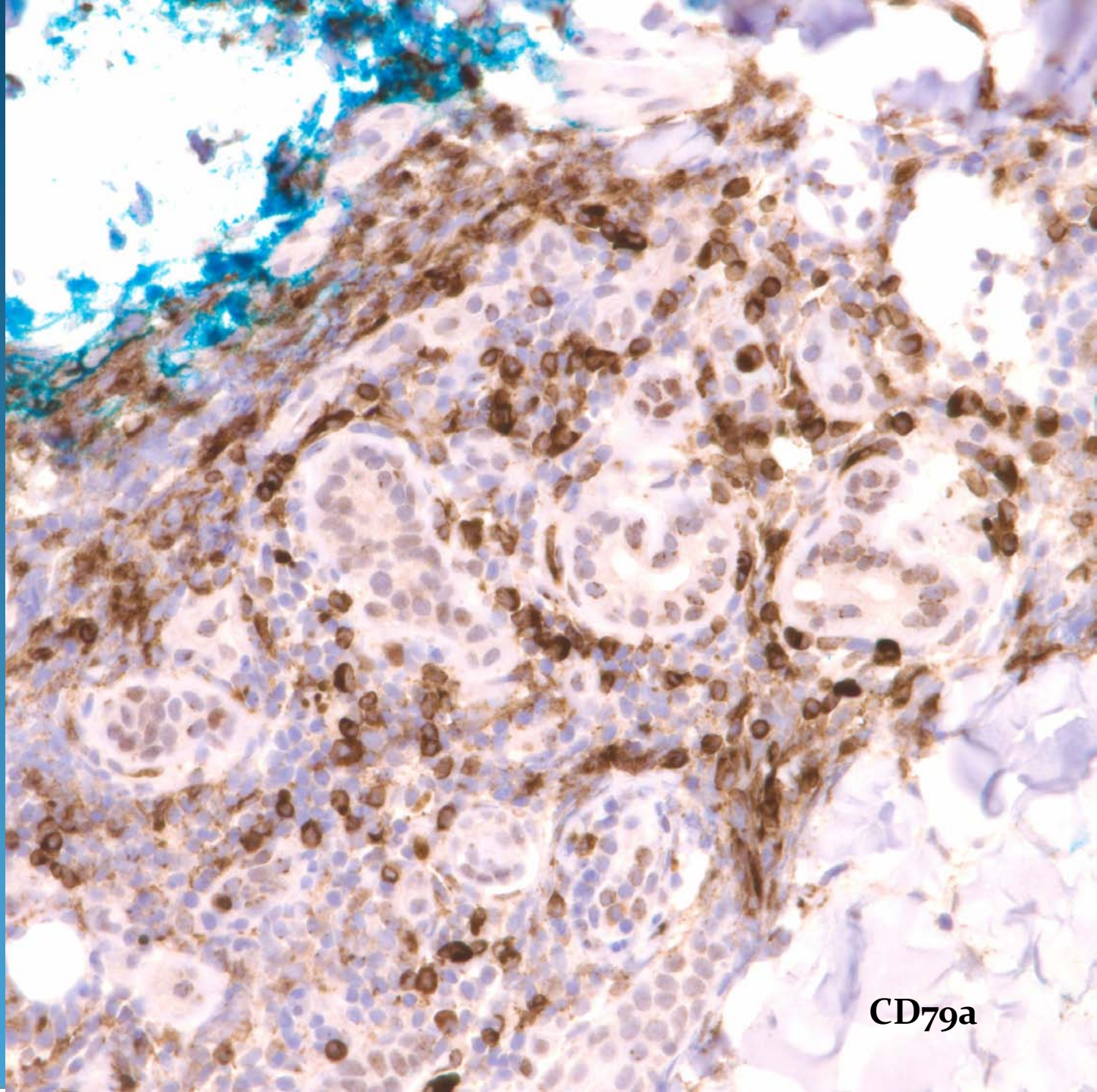


Cutaneous B-Cell Lymphoma (Marginal Zone Lymphoma)

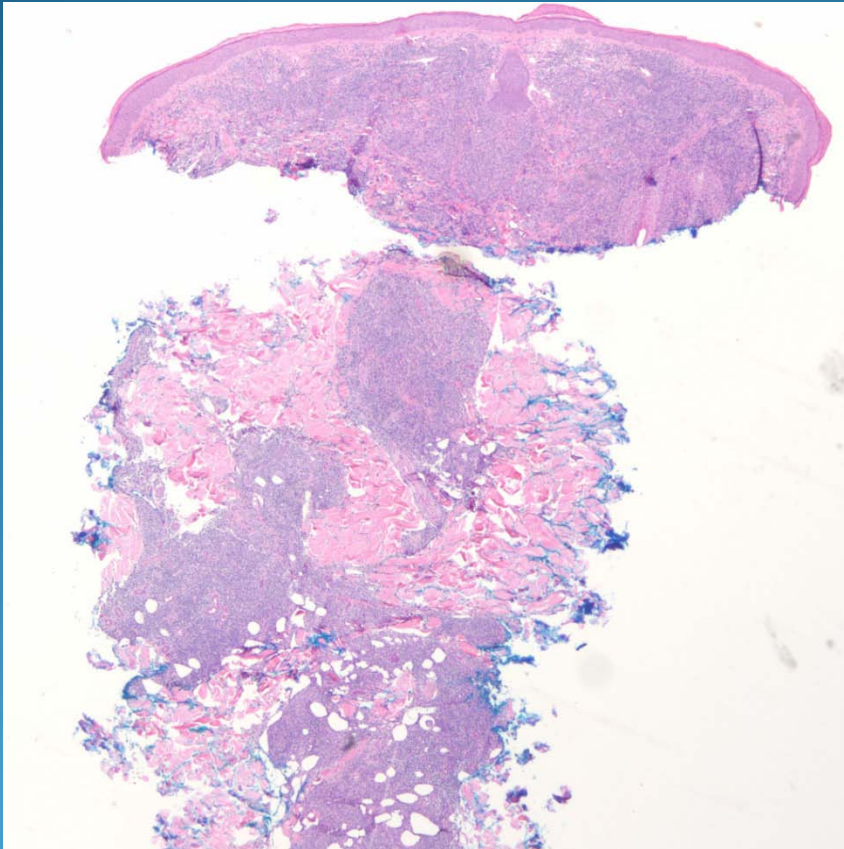


CD79a



CD79a

Pearls



- Nodular and diffuse lymphoid infiltrate
- Grenz zone separates infiltrate from epidermis
- Bottom heavy infiltrate extending into subcutaneous adipose tissue and adnexal structures
- May have increased plasma cells
- Confirm with IHC stains (CD20, CD79a+)